

PAPER • OPEN ACCESS

## Safety evaluation of *Terminalia catappa*Linn (Combretaceae) aqueous leaf extract: Sub-acute cardio-toxicopathological studies in albino Wistar rats

To cite this article: Franklyn Nonso Iheagwam *et al* 2019 *J. Phys.: Conf. Ser.* **1299** 012109

View the [article online](#) for updates and enhancements.



**ECS** **240th ECS Meeting**  
Oct 10-14, 2021, Orlando, Florida

**Register early and save  
up to 20% on registration costs**

Early registration deadline Sep 13

**REGISTER NOW**

## Safety evaluation of *Terminalia catappa* Linn (Combretaceae) aqueous leaf extract: Sub-acute cardio-toxicopathological studies in albino Wistar rats

Franklyn Nonso Iheagwam<sup>1,2\*</sup>, Chiamaka Obiageli Okeke<sup>1</sup>, Opeyemi Christianah DeCampos<sup>1,2</sup>, Daniel Uche Okere<sup>1</sup>, Olubanke Olujoke Ogunlana<sup>1,2</sup> and Shalom Nwodo Chinedu<sup>1,2</sup>

<sup>1</sup>Department of Biochemistry, Covenant University, P.M.B. 1023 Ota, Ogun State, Nigeria.

<sup>2</sup>Covenant University Public Health and Wellness Research Cluster (CUPHWERC), Covenant University, P.M.B. 1023 Ota, Ogun State, Nigeria.

\*Corresponding Author: [franklyn.iheagwam@covenantuniversity.edu.ng](mailto:franklyn.iheagwam@covenantuniversity.edu.ng)

**Abstract.** This study evaluated the safety of sub-acute administration of *Terminalia catappa* L. aqueous leaf extract (TCA) on cardiac biochemical parameters. Graded concentrations (200, 400 and 800 mg/kg) of TCA were orally administered daily for 28 days. Cardiac biochemical parameters of toxicity were thereafter accessed using standard methods for superoxide dismutase, peroxidase, glutathione-S-transferase, reduced glutathione, lipid peroxidation, protein levels, cholesterol, triglyceride, lactate dehydrogenase and creatinine kinase. TCA treatment did not alter the heart weight and cardiac biochemical parameters. Nonetheless, at 800 mg/kg, the antioxidant profile was significantly improved after TCA treatment. There was no mediated sign of treatment toxicity as well as a change in cardiac histological architecture. *T. catappa* aqueous leaf extract is relatively non-toxic to the heart at the experimental doses and also within the test period.

**Keywords:** *Terminalia catappa* L., sub-acute, toxicity, Cardiac, test period

### 1. INTRODUCTION

There is a heavy dependence on traditional medicine by Asian and African populace in the prevention and management of various diseases [1]. Accessibility, affordability and cultural acceptance have aided in the continuous ethnomedicinal use of numerous medicinal plants by a large part of the population in Nigeria to cope with the increasing incidence of chronic diseases and health-care overheads [2].

*Terminalia catappa* Linn (Combretaceae) (TC), is known for its edible fruit and nut. It is found in the tropics and widely distributed through the tropics, Asia subtropical regions, Australia and Africa [3]. Phytochemicals such as tannins, phenols, flavonoids, alkaloids, triterpenes, coumarins and others have been reported to be present in its leaf [4,5]. Anti-cancer, hepatoprotective, anti-HIV reverse transcriptase, anti-hepatitis, anti-inflammatory and aphrodisiac effects are some of the reported pharmacological activity present in various extracts of the leaves [6,7]. TC is employed by local medicine men in Southwest Nigeria as a general tonic to treat ailments such as wounds, haemorrhages, cardiovascular diseases and heart disorders [3]. In urban areas where TC is found, its leaves constitute a major part of metropolitan lignocellulosic waste. Various preparations of leaves are administered without any prior knowledge of their safe levels and cardio-toxic effect of long term consumption. The present study evaluated the consequence of sub-acute oral administration of *T. catappa* aqueous leaf extract on cardiac biochemical parameters.



## 2. MATERIALS AND METHOD

All chemicals and reagents acquired from Burguboyne, Sigma Aldrich and AnalR were of analytical grade.

### 2.1. Collection and Identification of Sample

Healthy *T. catappa* leaves were obtained from Covenant University and identified by Dr. J.O. Popoola from the Department of Biological Sciences, Covenant University. A voucher specimen was deposited in the herbarium with voucher number TC/CUBio/H809 and ascension code OgCuNo809.

### 2.2. Extract Preparations

The aqueous crude extract (TCA) was prepared as reported by Iheagwam *et al.*[8] with slight modification. Briefly, the leaves were washed, air dried at room temperature for two (2) weeks and crushed to a uniform size. Sample blend (500 g) was steeped in distilled water (10 L) for 72 h with periodical stirring. The obtained filtrate was concentrated using a rotary evaporator (Stuart, RE 300/MS, Staffordshire, UK) to yield an aqueous crude extract.

### 2.3. Experimental Animals

Adult male albino Wistar rats (n = 20) presumed to be healthy were purchased from the National Institute of Medical Research (NIMR), Lagos, Nigeria and housed in the Department of Biochemistry animal house in Covenant University. They were maintained with an alternating 12 hrs light and dark cycle, access to food and water *ad libitum* prior to and during the experimental period. The guidelines for the care and use of laboratory animals documented by the National Institute of Health for the Care and Use of Laboratory Animals was strictly adhered to. An approval (CHREC/031/2018) was granted by Covenant University Health, Research and Ethics Committee.

### 2.4. Sub-acute Toxicity Assessment Protocol

Rats (n = 20) were randomly divided into 4 groups (n=5) as projected in Table 1:

**Table 1:** Sub-acute assessment experimental design

| GROUPS    | TREATMENT                              | Rat No. |
|-----------|--|---------|
| Group I   | Normal rats treated with vehicle alone | 5       |
| Group II  | Rats treated with 200 mg/kg bwt of TCA | 5       |
| Group III | Rats treated with 400 mg/kg bwt of TCA | 5       |
| Group IV  | Rats treated with 800 mg/kg bwt of TCA | 5       |

Sub-acute toxicity was done according to the Organization for Economic Cooperation and Development (OECD) guidelines 423 as described by Ogunlana *et al.*[9]. Plant extract and vehicle were orally administered for 28 days and animals monitored for signs of toxicity. On the 28th day, after 12 h fasting, the rats were anaesthetized using a single dose combination of xylazine and ketamine (5 and 50 mg/kg, i.p respectively) and sacrificed by cardiac puncture. Blood collected was poured into heparin tubes while the heart was collected, rinsed with normal saline, dried and stored in -20°C freezer (Haier Thermocool, BD-719R6) until analysis. A sizeable portion of cardiac tissue was stored in 10% neutral buffered formalin for histopathological assessment. Plasma was obtained from whole blood by centrifugation at 4000 rpm for 5 mins. Homogenate was obtained from a portion of the heart, homogenized in ice-cold homogenization buffer pH 7.2 using a Teflon pestle homogenizer and centrifuged at 10,000 rpm for 15 min. The retrieved samples were stored at 4 °C and used for biochemical analysis.

### 2.5. Biochemical Analysis

The levels of superoxide dismutase (SOD) [10], peroxidase (Px) [11], glutathione-S-transferase (GST) [12], reduced glutathione (GSH) [13], lipid peroxidation (LPO) [14] and protein levels (TP) [15] were analysed in the heart according to standard procedures and methods at the end of the experimental period. Cardiac cholesterol (CHOL), cardiac triglyceride (TG), plasma lactate dehydrogenase (LDH) and plasma creatinine kinase (CK) activities were analyzed according to procedures described in the commercial kits (Randox Lab., England, UK).

## 2.6. Histopathological Analysis

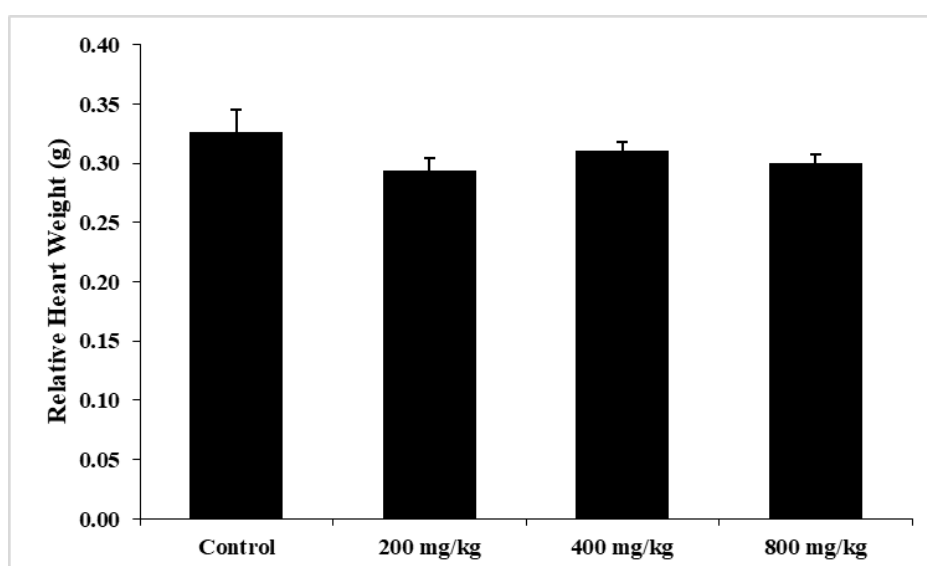
Histopathological assessment of cardiac tissues was adopted as reported by Chinedu *et al.*[16].

## 2.7. Statistical Analysis

Values were analysed using one-way analysis of variance (ANOVA) supplemented with Duncan post-hoc analysis using IBM SPSS Statistics 23 (IBM Corp., New York, USA). All results were reported as mean  $\pm$  standard error of mean (SEM) of five (5) replicates and, considered statistically significant at  $p < 0.05$ .

## 3. RESULTS

All treatment groups administered with various concentration (200 – 800 mg/kg) of the extract survived the experimental duration as no toxic sign was observed compared with the control group. Figure 1 depicts the effect of TCA on relative heart weight. In comparison with the control group, daily TCA administration did not alter the relative weight of the heart ( $p < 0.05$ ).



**Figure 1:** Effect of TCA on relative cardiac weight. Bars are represented as mean  $\pm$  SEM (n=5).

Table 2 shows the response of various cardiac antioxidant parameters after 28-day sub-acute TCA treatment. Daily TCA treatment significantly ( $p < 0.05$ ) increased GSH concentration as well as the activities of SOD and GST when compared with the control group. However, only the group administered with the highest dose (800 mg/kg) was able to significantly ( $p < 0.05$ ) increase Px activity with a concomitant significant ( $p < 0.05$ ) decrease in LPO concentration compared with the control.

**Table 2: Effect of TCA on cardiac antioxidant parameters (per mg protein)**

|                    | Control                     | 200 mg/kg                   | 400 mg/kg                   | 800 mg/kg                   |
|--------------------|-----------------------------|-----------------------------|-----------------------------|-----------------------------|
| <b>SOD (Units)</b> | 297.84 ± 39.15 <sup>a</sup> | 390.37 ± 66.58 <sup>b</sup> | 316.70 ± 55.61 <sup>a</sup> | 463.46 ± 41.18 <sup>b</sup> |
| <b>Px (Units)</b>  | 17.81 ± 2.36 <sup>a</sup>   | 18.31 ± 2.22 <sup>a</sup>   | 21.05 ± 1.15 <sup>a</sup>   | 32.67 ± 1.96 <sup>b</sup>   |
| <b>GST (Units)</b> | 122.26 ± 11.46 <sup>a</sup> | 139.71 ± 6.64 <sup>b</sup>  | 153.52 ± 14.39 <sup>b</sup> | 177.14 ± 15.62 <sup>c</sup> |
| <b>GSH (nM)</b>    | 33.60 ± 4.08 <sup>a</sup>   | 45.20 ± 4.18 <sup>b</sup>   | 41.40 ± 4.41 <sup>b</sup>   | 69.40 ± 4.81 <sup>c</sup>   |
| <b>LPO (µM)</b>    | 4.86 ± 0.91 <sup>a</sup>    | 4.19 ± 1.09 <sup>a</sup>    | 3.55 ± 0.96 <sup>a</sup>    | 2.55 ± 0.75 <sup>b</sup>    |

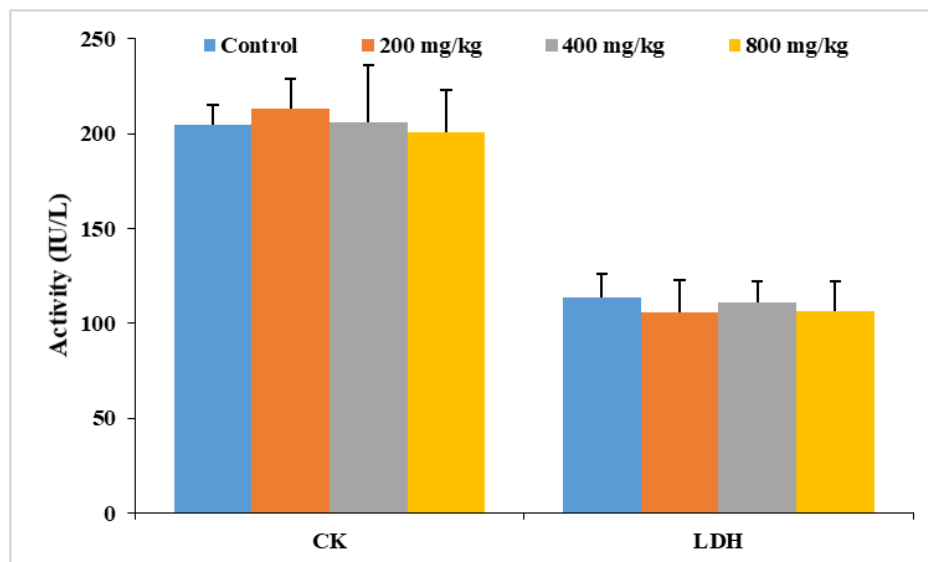
Values are represented as mean ± SEM (n=5). Data with different superscripts across a row are significantly different at p<0.05. Abbreviations: SOD - superoxide dismutase; Px - peroxidase; GST - glutathione-S-transferase; GSH - reduced glutathione; LPO - lipid peroxidation.

The effect of sub-acute administration of TCA on some biochemical parameters is represented in table 3. No significant change was observed in the concentration of cardiac CHOL, TG and TP in both the experimental and control group. The same observation was made in the activity of CK and LDH in the plasma between the control and administered groups (Figure 2). There was no significant change in the histological architecture of the heart of both experimental and control rats (Figure 3).

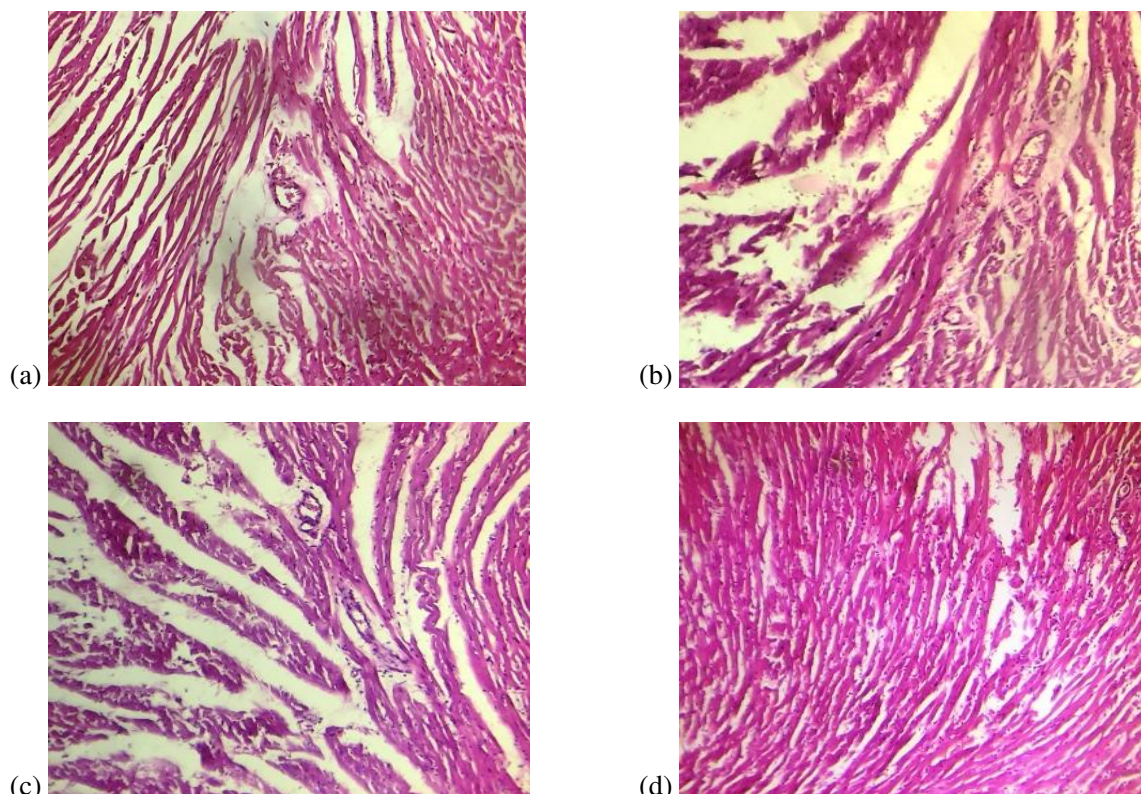
**Table 3: Effect of TCA on some cardiac biochemical parameters**

|                     | Control        | 200 mg/kg      | 400 mg/kg      | 800 mg/kg      |
|---------------------|----------------|----------------|----------------|----------------|
| <b>CHOL (mg/dL)</b> | 24.64 ± 7.42   | 23.89 ± 5.28   | 22.77 ± 10.37  | 26.54 ± 8.35   |
| <b>TG (mg/dL)</b>   | 122.65 ± 34.69 | 131.12 ± 41.35 | 126.28 ± 27.63 | 119.90 ± 30.44 |
| <b>TP (mg/mL)</b>   | 51.50 ± 0.92   | 55.17 ± 0.83   | 53.13 ± 1.34   | 55.27 ± 2.25   |

Values are represented as mean ± SEM (n=5). Abbreviations: CHOL - cholesterol; TG - triglyceride; TP - protein levels.



**Figure 2:** Activity of some heart function parameters after 28-day TCA treatment. Bars are represented as mean ± SEM (n=5). Abbreviations: LDH - lactate dehydrogenase; CK - creatinine kinase.



**Figure 3:** Histological sections from rat cardiac tissues of groups treated with (a) control (b) 200 mg/kg (c) 400 mg/kg (d) 800 mg/kg TCA. Photomicrographs reveals bundles of myocardial fibres, interstitial space and coronary artery (HE. 100X).

#### 4. DISCUSSION AND CONCLUSION

In this study, there were no clinical signs of morbidity, toxicity or mortality after sub-acute daily dose treatment with TCA. It can be deduced that TCA is relatively non-cardio-toxic at the experimental dose and time frame. Relative organ weight index is important in determining the toxicity of various compounds in experimental animals [17]. SOD and Px are first-line defence mechanisms against reactive oxygen species (ROS) under physiological and pathological condition thus, novel drugs mimicking their mechanism of action are used in the treatment of diseases associated with ROS [18]. GST is a phase 2 enzyme used to conjugate phase 1 activated toxic intermediates to ensure they are more polar and easily excreted. They exert this antioxidant property by transferring glutathione to these intermediates. For cardiac markers of oxidative stress, the significant decrease in lipid peroxidation of animals treated with 800 mg/kg indicates that malondialdehyde concentration was reduced. This alteration was compensated by the increase in GSH concentration, SOD, GST and Px activity, reducing the peroxidation of the cardiac lipid membrane. This indicates that TCA treatment helps maintain the antioxidant/oxidant system homeostasis [19]. Biochemical parameters alterations are effective pointers of organ damage and dysfunction. Since there was no alteration in the relative cardiac weight. It is a strong indicator that TCA may not have any adverse effect and/or toxicity on the heart. It is noteworthy, that inflammation and increased secretion by the organ is correlated with an increase in organ weight while a reduction could suggest cellular constriction. LDH and CK are enzymes found in the myocardial cells of the heart. When cardiac toxicity occurs, the integrity of the cardiac membrane is altered, leading to increased cell membrane permeability concomitantly increasing serum activity of these enzymes [20]. Analysis of plasma CK and LDH activity shown in figure 2 demonstrates that TCA treatment did not promote

significant alterations in these cardiac biomarkers of toxicity. This was further corroborated by histological examinations in which there was no pathological change on the cardiac architecture. Hence, TCA may not have any cardio-toxic effect thus, expanded cardiac muscle contraction, myocyte death and altered membrane permeability which are some hallmarks of cardiac toxicity as reported by El Shaer may be absent [21]. This was further verified by Sabiu *et al.* [22] that unnecrotised myocytes which portrayed uniform architectural arrangement, do not have altered cardiac biomarkers of toxicity. TCA administration showed no significant variation in the cardiac concentration of CHOL, TG and TP as earlier observed for the cardiac enzymes of toxicity. This may indicate that the extract did not alter the metabolism of these macromolecules in the heart. Our study reveals *T. catappa* aqueous leaves extract is relatively safe to use in the treatment of heart disorders. It also possesses antioxidant properties and thus validates its use in ethnomedicine. Further studies are however required to evaluate the safety of TCA administration on other tissues.

## REFERENCES

- [1] Ezuruike, U. F. and Prieto, J. M. 2014. *J. Ethnopharmacol.* **155(2)**, 857-924.
- [2] Abdullahi, A. A. 2011. *Afr. J. Tradit. Complement. Altern. Med.* **8(5S)**, 115–123.
- [3] Cock, I. E. 2015. *Inflammopharmacology.* **23(5)**, 203-229.
- [4] Vargas-Magaña, J. J., Torres-Acosta, J. F. J., Aguilar-Caballero, A. J., Sandoval-Castro, C. A., Hoste, H. and Chan-Pérez, J. I. 2014. *Vet. Parasitol.* **206(3-4)**, 322-327.
- [5] Katiki, L. M., Gomes, A. C. P., Barbieri, A. M. E., Pacheco, P. A., Rodrigues, L., Veríssimo, C. J., Gutmanis, G., Piza, A.M., Louvandini, H. and Ferreira, J. F. S. (2017). *Vet. Parasitol.* **246**, 118-123.
- [6] Chyau, C. C., Ko, P. T. and Mau, J. L. 2006. *LWT-Food Sci. Technol.* **39(10)**, 1099-1108.
- [7] Anand, A. V., Divya, N. and Kotti, P. P. 2015. *Pharmacog. Rev.* **9(18)**, 93–98.
- [8] Iheagwam, F. N., Nsedu, E. I., Kayode, K. O., Emiloju, O. C., Ogunlana, O. O. and Chinedu, S. N. 2018. *AIP Conf. Proceed.* **1954(1)**, 030015.
- [9] Ogunlana, O. O., Ogunlana, O. E., Adeneye, A. A., Udo-Chijioke, O. A. C., Dare-Olipede, T. I., Olagunju, J. A. and Akindahunsi, A. A. 2013. *Afr. J. Tradit. Complement. Altern. Med.* **10(6)**, 504-512.
- [10] Misra, H. P. and Fridovich, I. 1972. *J. Biol. Chem.* **247(10)**, 3170–3175.
- [11] Chance, B. and Maehly, A.C. 1955. *Methods Enzymol.* **2**, 773-775.
- [12] Dedeke, G. A., Iwuchukwu, P. O., Aladesida, A. A., Afolabi, T. A. and Ayanda, I. O. 2018. *Sci. Total Environ.* **624**, 576-585.
- [13] Sedlak, J. and Lindsay, R. H. 1968. *Anal. Biochem.* **25**, 1192–1205.
- [14] Buege, J. A. and Aust, S. D. 1978. *Methods Enzymol.* **52**, 302–310.
- [15] Lowry, O.H., Rosenbrough, N.J., Farr, A.L. and Randall, R.J. 1951. *J. Biol. Chem.* **193**, 265-275.
- [16] Chinedu, S. N., Iheagwam, F. N., Anichebem, C. J., Ogunnaike, G. B. and Emiloju, O. C. 2017. *J. Biol. Sci.* **17(8)**, 381-387.
- [17] Abdullahi, A. A. 2011. *Afr. J. Tradit. Complement. Altern. Med.* **8(5S)**, 115-123.
- [18] Batinić-Haberle, I., Rebouças, J. S. and Spasojević, I. 2010. *Antioxid. Redox Signal.* **13(6)**, 877-918.
- [19] de Lima, R., Guex, C. G., da Silva, A. R. H., Lhamas, C. L., dos Santos Moreira, K. L., Casoti, R., Dornelles, R.C., da Rocha, M.I.U.M., da Veiga, M.L., de Freitas Bauermann, L. and Manfron, M. P. 2018. *J. Ethnopharmacol.* **224**, 76-84.
- [20] Kumar, M., Kasala, E. R., Bodduluru, L. N., Dahiya, V. and Lahkar, M. 2016. *Inflamm. Res.* **65(8)**, 613-622.
- [21] El Shaer, S. S., Salaheldin, T. A., Saied, N. M. and Abdelazim, S. M. 2017. *Exp. Toxicol. Pathol.* **69(7)**, 435-441.
- [22] Sabiu, S., O'Neill, F. H. and Ashafa, A. O. T. 2017. *Trans. R. Soc. South Afr.* **72(3)**, 225-233.